

# Eruption of premolars subsequent to autotransplantation. A longitudinal radiographic study

Hans Ulrik Paulsen\* and Jens Ove Andreasen\*\*

\*Department of Orthodontics, Copenhagen Municipal Dental Health Service and \*\*Department of Oral Surgery and Oral Medicine, University Hospital, Copenhagen, Denmark

**SUMMARY** One-hundred-and-eighteen premolars transplanted at a stage with 3|4 to 4|4 root development with an open apical foramen were followed using a standardized clinical and radiographic technique for signs of periodontal ligament healing, root development, and tooth eruption. Root growth was unimpeded in 26 per cent, impaired in 55 per cent, and arrested in 19 per cent. Eruption of transplants occurred at the time of periodontal and alveolar healing, and before any significant root growth. Furthermore, autotransplanted premolars created growth of the alveolar process along with the eruption process.

## Introduction

Eruption and its rate for permanent teeth has been studied in humans using a variety of methods, such as radiography (Carlson, 1944; Burke, 1954; Darling and Levers, 1975, 1976; Paulsen and Andreasen, 1995), photography (Burke and Newell, 1958), video microscopy (Proffit *et al.*, 1991; Trentini *et al.*, 1995) and plaster models (Burke, 1963; Berkovitz and Bass, 1976; Smidt, 1980). Biochemical studies have been used in animals (Cahill *et al.*, 1988; Gorski *et al.*, 1994; Marks *et al.*, 1995). These studies have shown both a tooth development and an age-related relationship to tooth eruption. Furthermore, a relationship to daily rhythms (Proffit *et al.*, 1994; Lee and Proffit, 1995; Trentini *et al.*, 1995; Trentini and Proffit, 1996), and changes of proteins and enzymes in the dental follicle (Thesleff *et al.*, 1994; Wise *et al.*, 1994) have been shown. The precision of radiographic studies has been enhanced by the use of metallic implants which serve as fixed reference points within the jaws (Siersbæk-Nielsen, 1971; Björk and Skieller, 1972).

Eruption can be divided into six stages: two prior to gingival emergence (follicular growth, intra-bony migration) and four after the tooth emerges into oral cavity (prefunctional eruptive spurt, juvenile equilibrium, adolescent

acceleration, and adult equilibrium; Steedle and Proffit, 1985).

In a long-term study of 370 autotransplanted premolars by Andreasen *et al.* (1990c), it was shown that the peak of successful outcome of the optimal root length, periodontal ligament healing and pulp healing was recorded in stages 3–4 according to Moorrees *et al.* (1963; i.e. 3|4 to 4|4 root formation with a wide open apical foramen). These stages were in agreement with the general finding that most premolars erupt at a stage where 3|4 of the root formation has taken place (Grön, 1962; Haavikko, 1970; Demerjian *et al.*, 1973; Demerjian and Goldstein, 1976; Demerjian and Levesque, 1980; El Hadary and Shumaker, 1960).

The purpose of the present study was to analyse the pattern of eruptive movements of premolars subsequent to transplantation as they move from gingival emergence to the occlusal plane (extra-alveolar eruption) using distinct fixed points of trabecular structures in the alveolar medullary bone and to detect the influence of root growth on eruption of the transplants.

## Material and methods

Transplantations were performed by one surgeon (JOA) at the Department of Oral Surgery and Oral Medicine, University Hospital (RH),

**Table 1** Distribution of the 118 autotransplanted premolars in the group of patients with aplasia of permanent teeth or tooth loss due to trauma of the maxillary incisors.

		Total
Maxillary second premolars		
Mandibular second premolar regions	90	
Mandibular first premolar regions	2	
Contralateral side of the maxillary arch	2	
Replacement of maxillary central incisors	10	104
Mandibular second and first premolars		
Replacement of maxillary incisors	10	
Maxillary canine regions	4	14
Total		118

Copenhagen, whereas treatment plans and post-operative long-term controls were carried out by one author (HUP) at the Department of Orthodontics, Municipal Dental Health Service, Copenhagen, Denmark. Transplantation was used as an integrated therapy in orthodontic treatment of patients with aplasia of permanent teeth or tooth loss due to trauma of the maxillary incisors.

From the material in an earlier study (Andreasen *et al.*, 1990c), 118 premolars in stages 3–4 were selected (Table 1) and followed for a more detailed analysis of the tooth eruption pattern (Paulsen *et al.*, 1995; Paulsen and Andreasen, 1995). The transplants were followed longitudinally with a standardized clinical and radiographic technique (Andreasen and Andreasen, 1985; Andreasen *et al.*, 1990a) to examine tooth eruption at 1, 3, 4, 6, 8, 12, 16, 20, and 24 weeks after surgery, and yearly thereafter (range 6–18 years).

From the group of 90 maxillary second premolars transplanted to the region of the mandibular second premolar, 24 premolars transplanted with the cusp at gingival level were selected for the specific study of eruption.

Periodontal ligament healing (Andreasen *et al.*, 1990b) and root growth (Andreasen *et al.*, 1990c) subsequent to transplantation were monitored from radiographic examination as well as tooth eruption. Trabecular structures have been described as relatively stable in the jaws (Björk

and Skieller, 1972) and using these distinct structures as a reference, the prefunctional eruption of transplants was analysed from radiographs. A point representing distinct trabecular structures in the alveolar bone was selected as a measuring point to provide a reliable reference. Tooth eruption was measured as the distance from the cusp tip to the reference structure in the bone. Root growth was evaluated from successive radiographs, measured as the difference in tooth length from the cusp tip to the apex. A Jocal digital sliding calliper (C. E. Johansson AB, Eskilstuna, Sweden) read to the nearest 0.1 mm, was used to measure the distance between distinct structures in the anatomy of the medullary bone, tooth eruption, and tooth length. All measurements were repeated and a mean calculated. In no case was a difference more than 0.2 mm registered between the individual measurements.

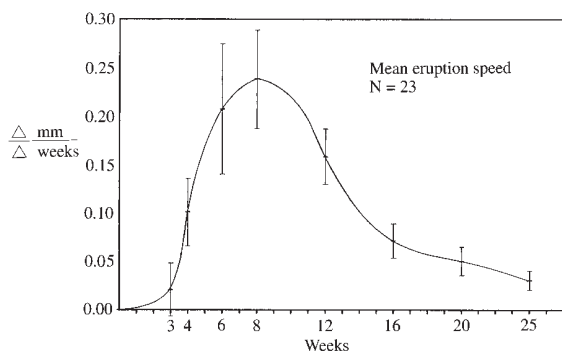
The direction and speed of eruption were examined by drawing superimposed sketches from radiographs based on the distinct trabecular structures as location references. The radiographs were mounted in 3-mm slide mounts and projected with two parallel slide projectors with a standardized focus distance and set up. The speed of eruption of the transplant related to the neighbouring reference teeth, was analysed in one case using:

- (1) the distance to a plane between the buccal cusp of the first premolar and the distobuccal cusp on the first molar;
- (2) alternatively, the cusp tip of the first premolar, as a reference.

#### *Criteria for healing and complications*

Pulp healing was evaluated clinically by an electrometric test (Siemens Sirotest II, Siemens, Munich, Germany), and radiographically for signs of pulp canal obliteration by a standardized radiographic technique using XCP film holders (Rinn Corp., Elgin, IL, USA) and a fixed film-focus distance of 33 cm.

Pulp necrosis was considered to be present when there were radiographic signs of a periapical radiolucency and/or inflammatory root resorption plus a negative response to electrometric



**Figure 1** The eruption speed of 23 autotransplanted premolars from gingival level to occlusal contact. Data are expressed as the mean  $\pm$  SEM.

sensitivity testing. Where an absence of pulp sensitivity was the only sign of pulp necrosis, a further requirement was that the pulp canal showed no sign of obliteration 6 months after transplantation.

Periodontal healing, root growth, and tooth eruption subsequent to transplantation were also monitored by radiographic examination and classified as being complete when the root periphery was entirely surrounded by a newly-formed periodontal space of a normal size.

Inflammatory root resorption was defined by the presence of bowl-shaped resorption cavities on the root surface associated with similar resorption cavities in the adjacent alveolar bone.

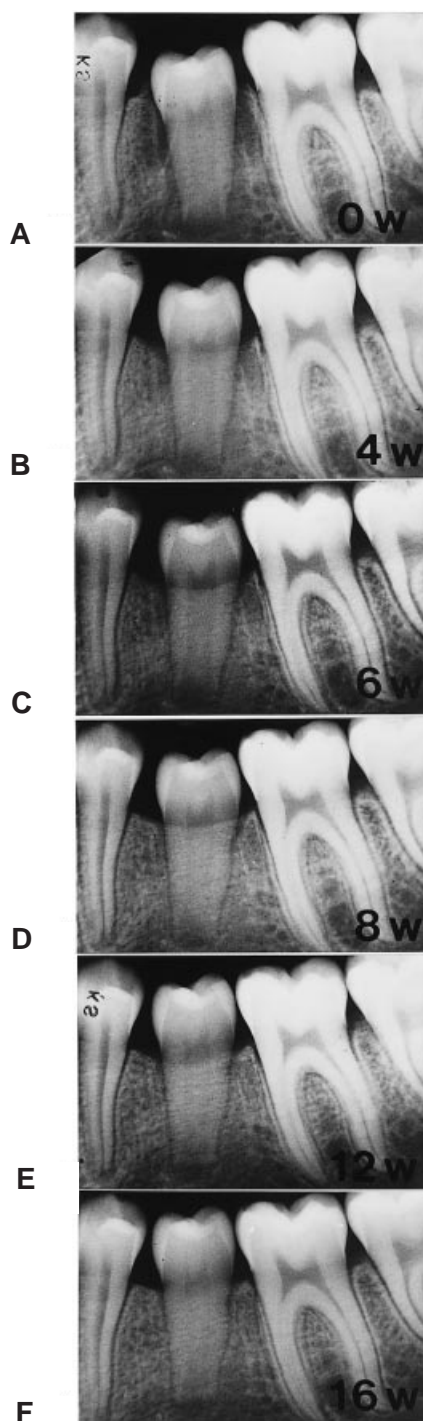
Replacement root resorption (ankylosis) presented a disappearance of the periodontal ligament space with or without resorption of the root. Clinically, the percussion test showed a high metallic percussion sound.

Root growth was evaluated from successive radiographs in millimetres and tooth length was measured from the cusp tip to the apex with the sliding calliper to the nearest 0.1 mm.

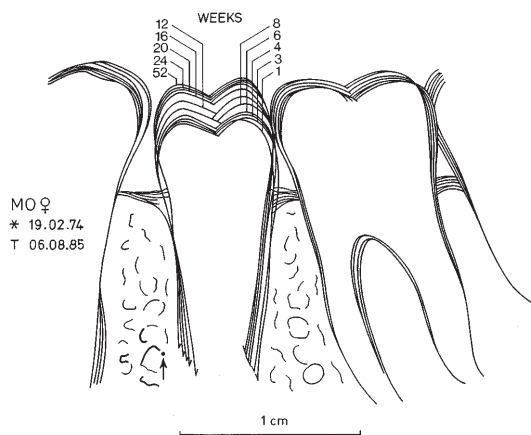
## Results

### *Pulp healing*

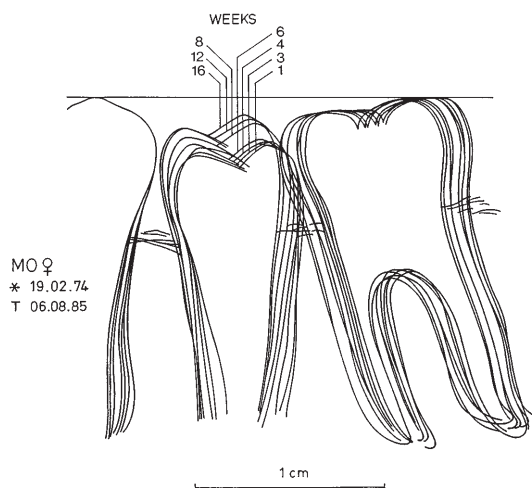
Sixteen teeth showed pulp necrosis and this condition was usually detected around 6 months after transplantation. One tooth had partial pulp



**Figure 2** A transplant with normal root development. Radiographs show healing after surgery: (A) a few days; (B) 4 weeks; (C) 6 weeks; (D) 8 weeks; (E) 12 weeks; (F) 16 weeks. Please also refer to schematics in Figures 3, 4 and 5.



**Figure 3** Drawing of radiographs from the transplant. The speed of eruption based on distinct structures in the trabecular structures of the medullary bone. The selected measuring point is marked with an arrow.

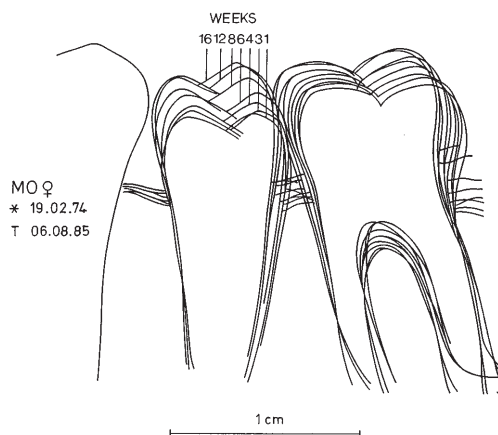


**Figure 4** Drawing of radiographs from the transplant. The speed of eruption based on neighbouring reference teeth, using the distance to a plane between the buccal cusp of the first premolar and the distobuccal cusp on the first molar, as a reference.

necrosis. Teeth with pulp necrosis and associated inflammatory resorption, could be detected at 2 months after transplantation.

#### *Periodontal healing*

This, as demonstrated radiographically, showed partial periodontal ligament healing after 4 weeks.



**Figure 5** Drawing of radiographs from the transplant. The speed of eruption based on neighbouring reference teeth, using the buccal cusp of the first premolar, as a reference.

The majority of transplants showed complete periodontal healing 8 weeks after transplantation. Inflammatory root resorption was seen in four cases, usually diagnosed 1–2 months after transplantation. Replacement root resorption (ankylosis) occurred in five cases. This complication was diagnosed within 6 weeks of transplantation.

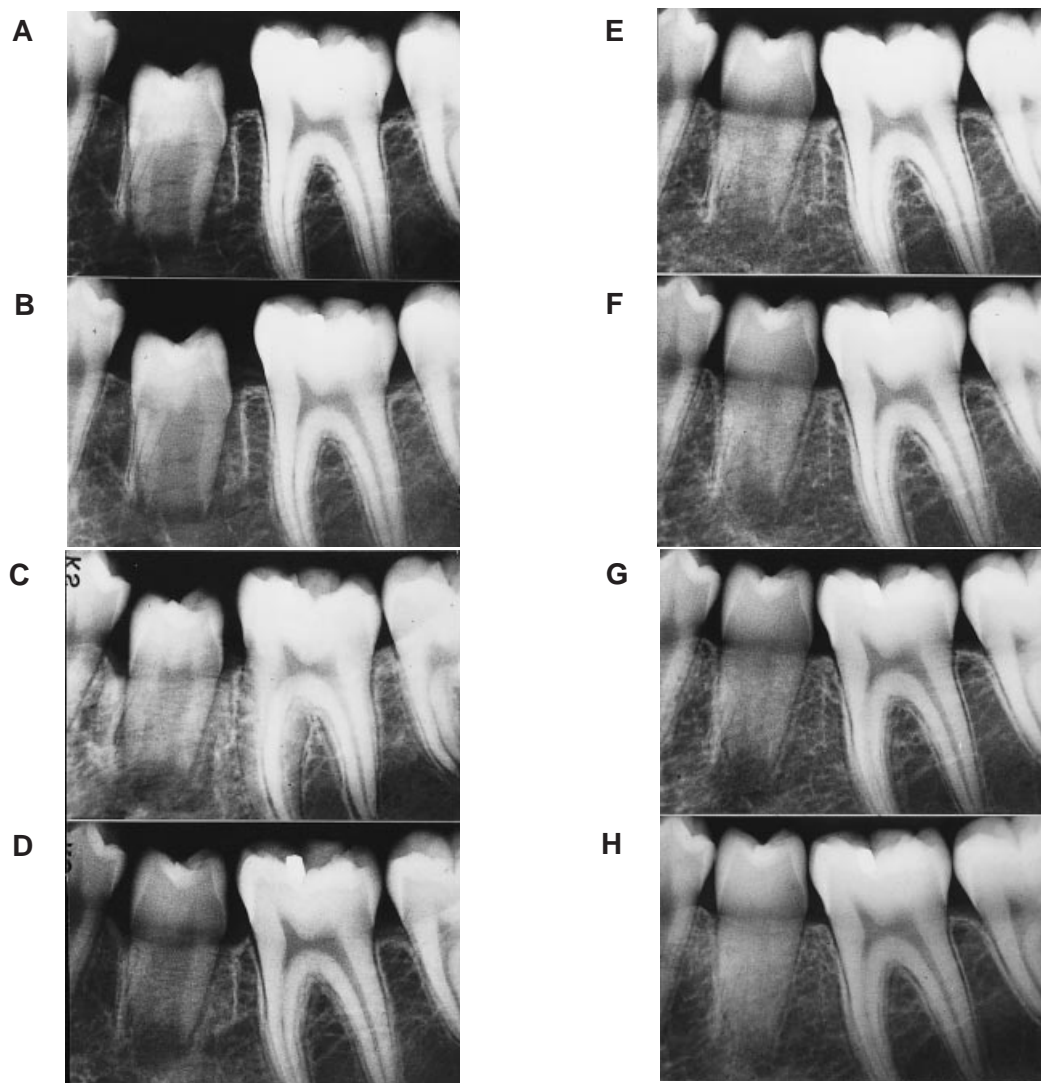
#### *Root growth*

Using a qualitative analysis of root development it was found that root growth was unimpeded in 26 per cent, impaired in 55 per cent, and arrested in 19 per cent.

#### *Tooth eruption*

This took place from 3 to 24 weeks after transplantation (Figure 1). The speed of eruption accelerated from 3 to 6 weeks after transplantation, was fastest in the period 6–12 weeks, and declined after 12–24 weeks when the transplant approached the occlusal plane and before any significant root growth had occurred.

The maximal eruption rate was 0.24 mm/week ( $\pm 0.05$  mm) 8 weeks after transplantation. Eruption distance from gingival emergence to the occlusal plane was 2.4 mm ( $\pm 0.2$  mm, range 1.2–5.0 mm) over 24 weeks. When the occlusal plane



**Figure 6 (A-H)** A transplant with normal root development. Radiographs show healing and eruption after surgery: (A) 1 week; (B) 3 weeks; (C) 4 weeks; (D) 6 weeks; (E) 8 weeks; (F) 12 weeks; (G) 20 weeks; (H) 24 weeks.

had been reached a very slow, but continuous eruption was recorded at a similar rate to the adjacent teeth. Data are expressed as the mean  $\pm$  SEM. Net eruptive movements averaging 7–29  $\mu$ m occurred from one day to the next until the tooth had erupted into occlusion at 24 weeks.

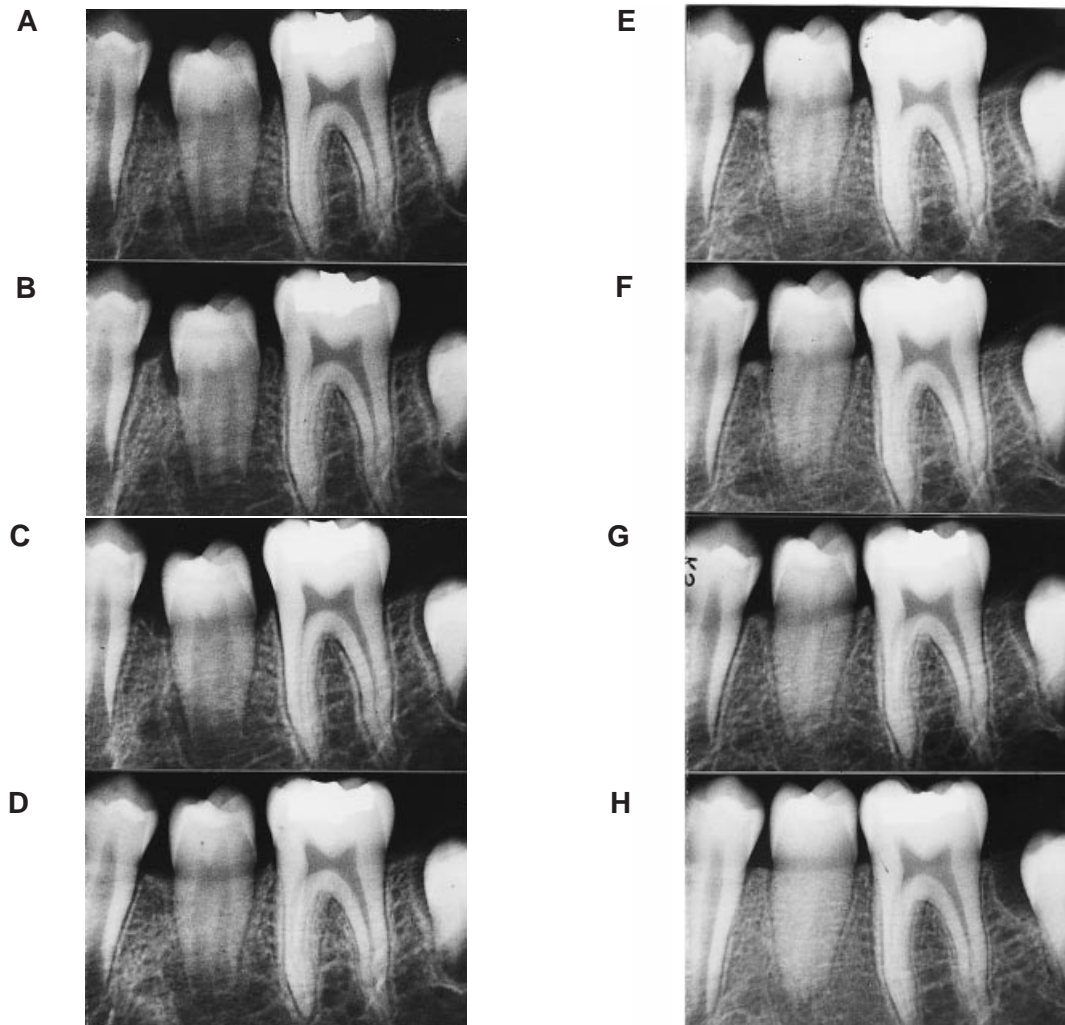
One tooth with replacement root resorption (ankylosis) showed no sign of eruption and was

therefore excluded from the calculation of the eruption rate of transplants.

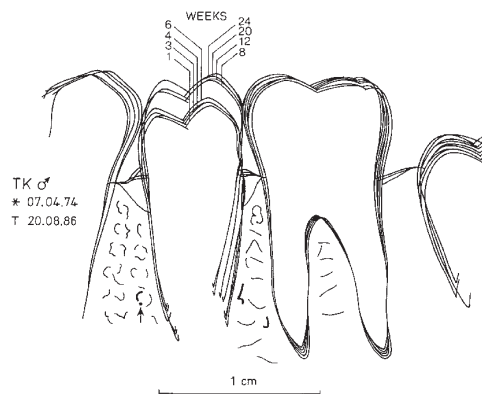
#### *Case presentations*

Three different types of root development and periodontal healing of transplants were selected to show the effect on tooth eruption.

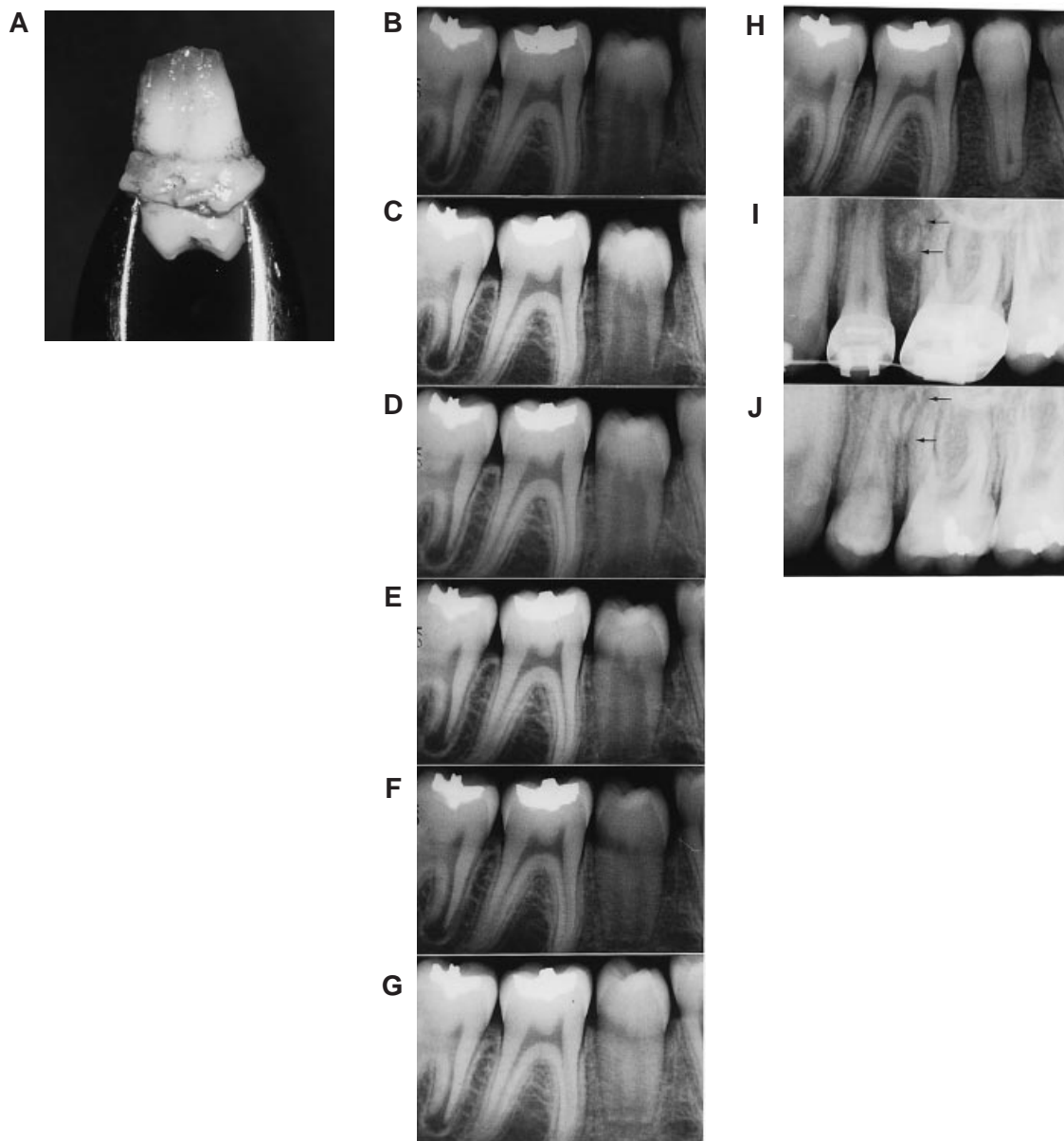




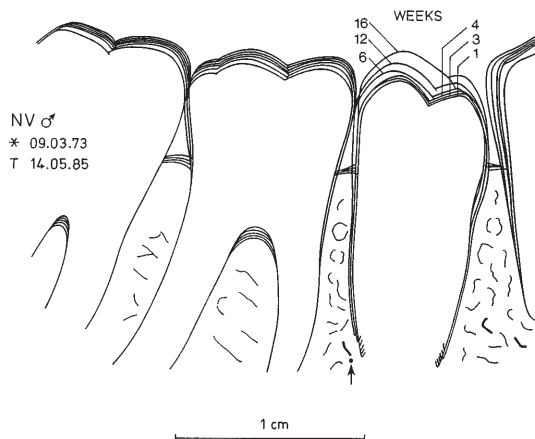
**Figure 7** (A-H) A transplant with impaired root development. Radiographs show healing and eruption after surgery: (A) 1 week; (B) 3 weeks; (C) 4 weeks; (D) 6 weeks; (E) 8 weeks; (F) 12 weeks; (G) 20 weeks; (H) 24 weeks.



**Figure 8** Drawing of radiographs from the transplant. The speed of eruption based on distinct structures in the trabecular structures of the medullary bone. The selected measuring point is marked with an arrow.



**Figure 9** (A) A transplant with arrested root development. The specimen during surgery. Note: the broken apex region. (B–J) Radiographs show healing and eruption after surgery: (B) a few days; (C) 3 weeks; (D) 1 month; (E) 6 weeks; (F) 3 months; (G) 4 months; (H) 9 months and after 1 month orthodontic rotation of the transplant; (I) donor region 9 months after surgery. Note: the newly formed apex. (J) Donor region 16 months after surgery. Note: the apex has grown.



**Figure 10** Drawing of radiographs from the transplant. The speed of eruption based on distinct structures in medullary bone. The selected measuring point is marked with an arrow.

Transplants with normal root development are illustrated by two examples; radiographs of both examples (Figures 2 and 6) and drawings of the first example (Figures 3, 4 and 5); Figure 3 shows the speed of eruption based on distinct trabecular structures as location references. The selected reference point was marked in the medullary bone. Furthermore, the speed of eruption of the transplant compared with neighbouring reference teeth is illustrated. Figure 4 used the distance to a plane between the buccal cusp of the first premolar and the distobuccal cusp on the first molar, while Figure 5 used the cusp tip of the first premolar, as a reference.

Transplants with impaired root development are illustrated in Figures 7 and 8 and those with arrested root development in Figures 9 and 10. A transplant with replacement root resorption (ankylosis) is illustrated by radiographs (Figure 11).

## Discussion

It has been stated that a second mandibular premolar can erupt 4.5 mm over a 14-week period after gingival emergence, a daily average of 46  $\mu\text{m}$  (Smidt, 1980). Proffit *et al.* (1991) have pointed out: 'It can be very difficult to measure tooth

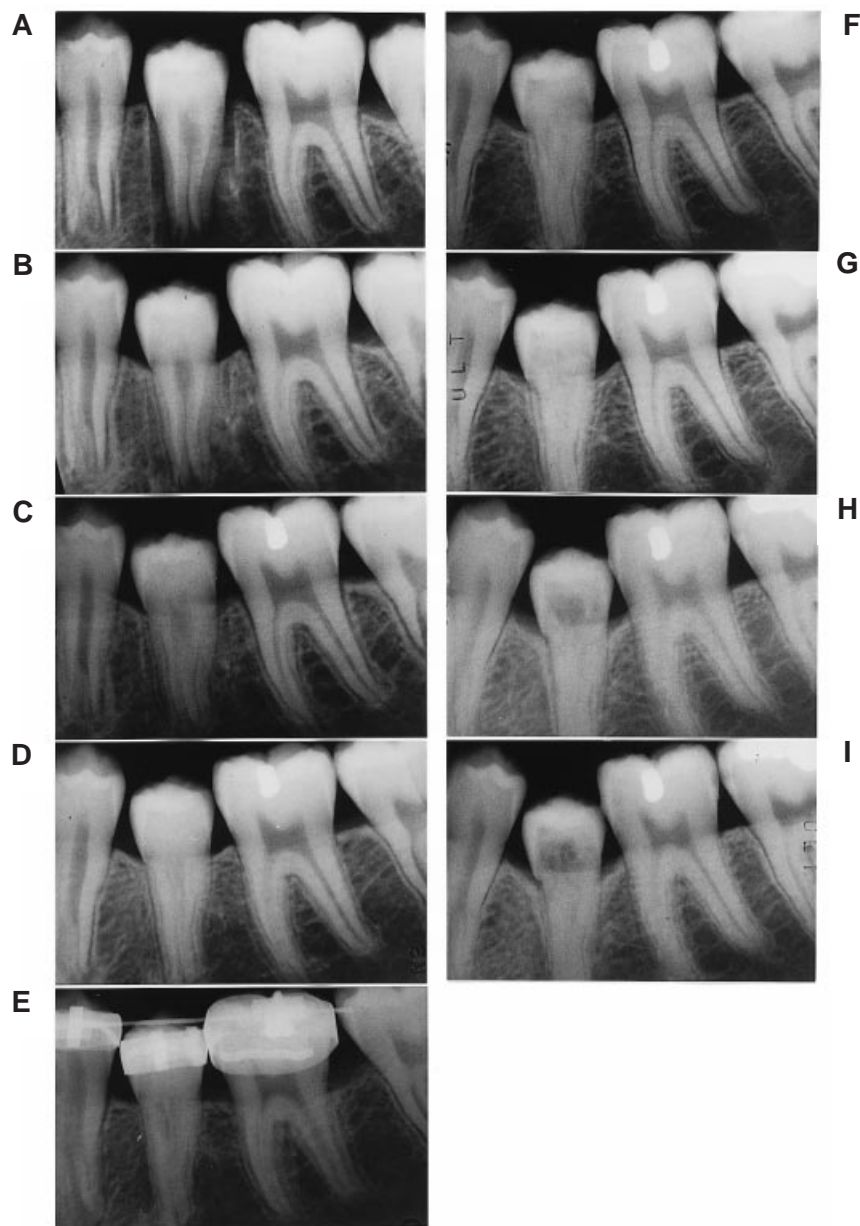
eruption precisely enough to evaluate the details of the eruptive process'. They showed, by use of a video microscope, that net eruptive movements averaging 25–75  $\mu\text{m}$  occurred from one day to the next until the tooth was almost in occlusion. Using the neighbouring teeth as a reference they followed the daily rhythm of tooth eruption.

In this study anatomical markers were used as reference points. Ideally, implants should have been placed as reference points for repeated radiographic examinations, but for ethical reasons this was not possible. Björk and Skieller (1972), in their study of facial development and tooth eruption, used metallic implants. They showed that distinct trabecular structures in the alveolar process were relatively stable. These structures were therefore used in the present study as reference points.

It appears from Figure 1 that eruption speed accelerated from 3 to 6 weeks after transplantation. This period correlates with periodontal healing after transplantation (Nordenram, 1963; Andreassen, 1981). Furthermore, the maximum speed of eruption was found 6–12 weeks after transplantation. This period correlates well with the end stage of immature bone formation in normal socket healing where the socket is almost completely occupied by immature bone (Amler, 1993). This correlation is presently under further investigation. The mean eruptive movements averaging 7–29  $\mu\text{m}$  occurred from one day to the next until the tooth had erupted into occlusion at 24 weeks. The eruption speed accelerated from 3 to 6 weeks after transplantation, was fastest in the period 6–12 weeks, and declined 12–24 weeks after transplantation, when the transplant approached the occlusal plane. This bell-shaped change in eruption speed apparently differs from normal emergence of premolars (Steedle and Proffit, 1985). They found that the rate of movement for the eruptive spurt was maximal at the time of gingival emergence. From that point on, the eruptive rate slowed as the tooth approached the occlusal plane, and came under the influence of masticatory and other intra-oral forces.

Tooth eruption after transplantation depends on wound healing. The fibroblasts will produce and replicate collagen with a high rate of turnover. The newly synthesized collagen fibrils will





**Figure 11** A transplant with normal root development but replacement root resorption. Radiographs show healing after transplantation: (A) a few days; (B) 12 weeks; (C) 24 weeks; (D) 1 year; (E) 2 years. Note: orthodontic force to accelerate eruption was applied to the ankylosed tooth immediately after surgical luxation. (F) Three years; (G) 4 years; and (H) 5 years after transplantation. The treatment result was unsuccessful with pronounced infraposition of the transplant during puberty. (I) Seven years after transplantation with marked internal resorption of the crown. The relative eruption of neighbouring teeth has resulted in further infraposition of the transplant.

re-organize the periodontal ligament with an increase in tensile strength during wound healing and thereby push the tooth to erupt. From the third week, a new socket has been formed and the newly-developed periodontal fibres extending from the cement to the alveolar surface might cause the tooth to erupt. Furthermore, the autotransplanted premolars create new alveolar growth along with the eruption process.

In contrast, the autotransplanted premolar with ankylosis (Figure 11) showed the same reaction as implants with osseointegration; disturbance in jaw growth will be found if implants are installed before termination of alveolar growth (Andreasen *et al.*, 1993).

## Conclusions

This study indicates that eruption of immature autotransplanted premolars takes place at a time when maximum periodontal and alveolar healing occurs, before any significant root growth. Thus, root growth of autotransplanted teeth is apparently not associated with pre-functional (extra-alveolar) eruption. Furthermore, autotransplanted premolars created growth of the alveolar process along with the eruption process.

## Address for correspondence

Hans Ulrik Paulsen  
Department of Orthodontics  
Copenhagen Municipal Dental Health Service  
Peder Lykke School  
Brydes Allé 25  
DK-2300 Copenhagen S  
Denmark

## Acknowledgement

This study was supported by the Danish Dental Association and Colgate-Palmolive A/S.

## References

- Amler M H 1993 Age factor in human alveolar bone repair. *Journal of Oral Implantology* 19: 138–142
- Andreasen J O 1981 Periodontal healing after replantation and autotransplantation of incisors in monkeys. *International Journal of Oral Surgery* 10: 54–61
- Andreasen F M, Andreasen J O 1985 Diagnosis of luxation injuries: the importance of standardized clinical, radiographic and photographic techniques in clinical investigations. *Endodontics Dental Traumatology* 4: 160–169
- Andreasen J O, Paulsen H U, Yu Z, Ahlquist R, Bayer T, Schwartz O 1990a A long-term study of 370 autotransplanted premolars. Part I. Surgical procedure and standardized techniques for monitoring healing. *European Journal of Orthodontics* 12: 3–13
- Andreasen J O, Paulsen H U, Yu Z, Schwartz O 1990b A long-term study of 370 autotransplanted premolars. Part III. Periodontal healing subsequent to transplantation. *European Journal of Orthodontics* 12: 25–37
- Andreasen J O, Paulsen H U, Yu Z, Bayer T 1990c A long-term study of 370 autotransplanted premolars. Part IV. Root development subsequent to transplantation. *European Journal of Orthodontics* 12: 38–50
- Andreasen J O *et al.* 1993 Implants in the anterior region. In: Andreasen J O, Andreasen F M (eds) *Textbook and color atlas of traumatic injuries to the teeth*. Munksgaard, Copenhagen
- Berkovitz B K B, Bass T P 1976 Eruption rates of human upper third molars. *Journal of Dental Research* 55: 460–464
- Björk A, Skieller V 1972 Facial development and tooth eruption. An implant study at the age of puberty. *American Journal of Orthodontics* 62: 339–383
- Burke P H 1954 Eruption analysis of maxillary first incisors in a patient with unilateral absence of a second incisor. *Transactions of the European Orthodontic Society*, pp. 343–349
- Burke P H 1963 Eruptive movements of permanent maxillary central incisor teeth in the human. *Proceedings of the Royal Society of Medicine* 56: 513–515
- Burke P H, Newell D J 1958 A photographic method of measuring eruption of certain human teeth. *American Journal of Orthodontics* 44: 590–602
- Cahill D R, Marks S C, Wise G E, Gorski J P 1988 A review and comparison of tooth eruption systems used in experimentation – a new proposal on tooth eruption. In: Davidovitch Z (ed.) *The biological mechanisms of tooth eruption and root resorption*. EBSCO Media, Birmingham, pp. 1–7
- Carlson H 1944 Studies on the rate and amount of eruption of certain human teeth. *American Journal of Orthodontics* 30: 575–588
- Darling A I, Levers B G 1975 The pattern of eruption of some human teeth. *Archives of Oral Biology* 20: 89–96
- Darling A I, Levers B G 1976 The pattern of eruption. In: Poole D F G, Stack M V (eds) *The eruption and occlusion of teeth*. Butterworth & Co, Ltd, London, pp. 80–96
- Demirjian A, Goldstein H 1976 New systems for dental maturity based on seven and four teeth. *Annals of Human Biology* 3: 11–421
- Demirjian A, Levesque G-Y 1980 Sexual differences in dental development and prediction of emergence. *Journal of Dental Research* 59: 1110–1122

- Demerjian A, Goldstein H, Tanner J M 1973 A new system of dental age assessment. *Human Biology* 45: 211–227
- Gorski J P, Brown K M, Marvin M, Wise G E, Marks S C Jr 1994 Eruption of premolars subsequent to transplantation. In: Davidovitch Z (ed.) *The biological mechanisms of tooth eruption, resorption and replacement by implants*. Harvard Society for the Advancement of Orthodontics, Boston, pp. 397–406
- Grön A-M 1962 Prediction of tooth emergence. *Journal of Dental Research* 4: 573–585
- Haavikko K 1970 The formation and the alveolar emergence. *Journal of Dental Research* 41: 573–585
- Lee C F, Proffit W R 1995 The daily rhythm of tooth eruption. *American Journal of Orthodontics and Dentofacial Orthopedics* 107: 38–47
- Marks S C Jr, Gorski J P, Wise G E 1995 The mechanisms and mediators of tooth eruption. Models for developmental biologists. *International Journal of Developmental Biology* 39: 223–230
- Moorrees C F A, Fanning E A, Hunt E E Jr 1963 Age variation of formation stages for 10 permanent teeth. *Journal of Dental Research* 42: 1490–1502
- Nordenram Å 1963 Autotransplantation of teeth. A clinical and experimental investigation. *Acta Odontologica Scandinavica* 21, Suppl 33
- Paulsen H U, Andresen J O 1995 Tooth eruption subsequent to transplantation: A longitudinal radiographic study of autotransplanted premolars. *European Journal of Orthodontics* 17: 348 (Abstract)
- Paulsen H U, Andreasen J O, Schwartz O 1995 Pulp survival, periodontal healing and root development of autotransplanted premolars in orthodontic treatment. *American Journal of Orthodontics and Dentofacial Orthopedics* 108: 630–640
- Proffit W R, Prewitt J R, Baik H S, Lee C F 1991 Video microscope observations of human premolar eruption. *Journal of Dental Research* 1: 15–18
- Proffit W R, Almeida M A, Lee C F P 1994 What controls the daily rhythm of tooth eruption? In: Davidovitch Z (ed.) *The biological mechanisms of tooth eruption, resorption and replacement by implants*. Harvard Society for the Advancement of Orthodontics, Boston, pp. 355–370
- Shumaker D B, El Hadary M S 1960 Roentgenographic study of eruption. *Journal of American Dental Association* 61: 535–541
- Siersbæk-Nielsen S 1971 Rate of eruption of central incisors at puberty: an implant study on eight boys. *Danish Dental Journal* 75: 1288–1295
- Smidt R G 1980 A clinical study into the rate of eruption of some human permanent teeth. *Archives of Oral Biology* 23: 675–681
- Steedle J R, Proffit W R 1985 The pattern and control of eruptive tooth movements. *American Journal of Orthodontics* 87: 56–66
- Thesleff I, Sahlberg C, Reponen P, Tryggvason, K 1994 Matrix remodeling during tooth and bone development: the expression of gelatinases A and B and TGF growth factors. In: Davidovitch Z (ed.) *The biological mechanisms of tooth eruption, resorption and replacement by implants*. Harvard Society for the Advancement of Orthodontics, Boston, pp. 355–370
- Trentini C J, Proffit W R 1996 High-resolution observations of human premolar eruption. *Archives of Oral Biology* 41: 63–68
- Trentini C J, Brown W H, Paterson R L, Proffit W R 1995 The application of Moire magnification to high-resolution studies of human premolar eruption. *Archives of Oral Biology* 40: 623–629
- Wise G E, Lin F, Marks S C Jr, Gorski J P 1994 The molecular basis of tooth eruption. In: Davidovitch Z (ed.) *The biological mechanisms of tooth eruption, resorption and replacement by implants*. Harvard Society for the Advancement of Orthodontics, Boston, pp. 383–395